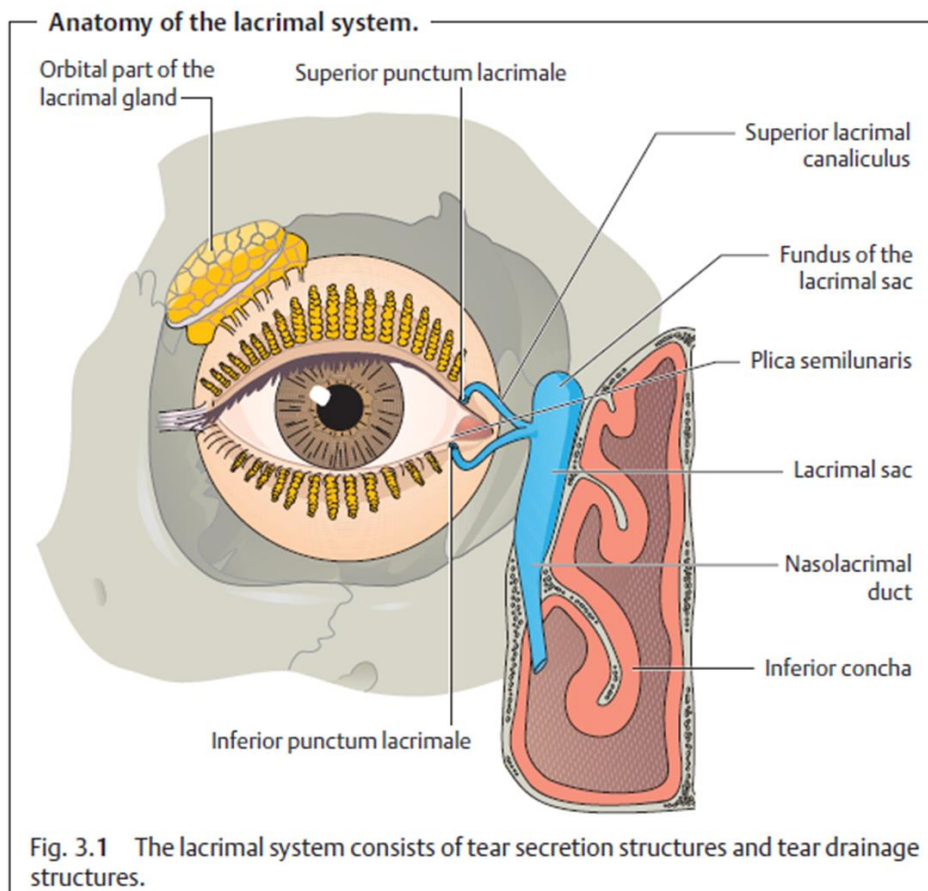


# Lacrimal system

## Basic Knowledge

The lacrimal system consists of two sections

- Structures that secrete tear fluid.
- Structures that facilitate tear drainage.



## Position, structure, and nerve supply of the lacrimal gland:

- The **lacrimal gland** is about the **size of a walnut**; it lies beneath the superior temporal margin of the orbital bone in the lacrimal fossa of the frontal bone and is *neither visible nor palpable*.
- A palpable lacrimal gland is usually a sign of a pathologic change such as **dacryoadenitis**.

- The tendon of the levator palpebrae muscle divides the lacrimal gland into a *larger orbital part* (two-thirds) and a *smaller palpebral part* (one-third).
- Several tiny **accessory lacrimal glands (glands of Krause and Wolfring)** located in the superior fornix secrete additional serous tear fluid.
- The lacrimal gland receives its **sensory supply** from the *lacrimal nerve*.
- Its **parasympathetic secretomotor** nerve supply comes from the *nervus intermedius*.
- The **sympathetic fibers** arise from the **superior cervical sympathetic ganglion** and follow the course of the blood vessels to the gland.

## Tear film

The tear film that moistens the conjunctiva and cornea is composed of **three layers**:

1. The **outer oily layer** (approximately 0.1  $\mu\text{m}$  thick) is a product of the *meibomian glands* and the *sebaceous glands and sweat glands of the margin of the eyelid*. The primary function of this layer is to stabilize the tear film.

- With its hydrophobic properties, it prevents rapid evaporation like a layer of wax.

2. The **middle watery layer** (approximately 8  $\mu\text{m}$  thick) is produced by the *lacrimal gland* and the *accessory lacrimal glands* (glands of Krause and Wolfring).

**Its functions are:**

- A. Clean the surface of the cornea
- B. Ensure mobility of the palpebral conjunctiva over the cornea and
- C. Ensure a smooth corneal surface *for high-quality optical images*.

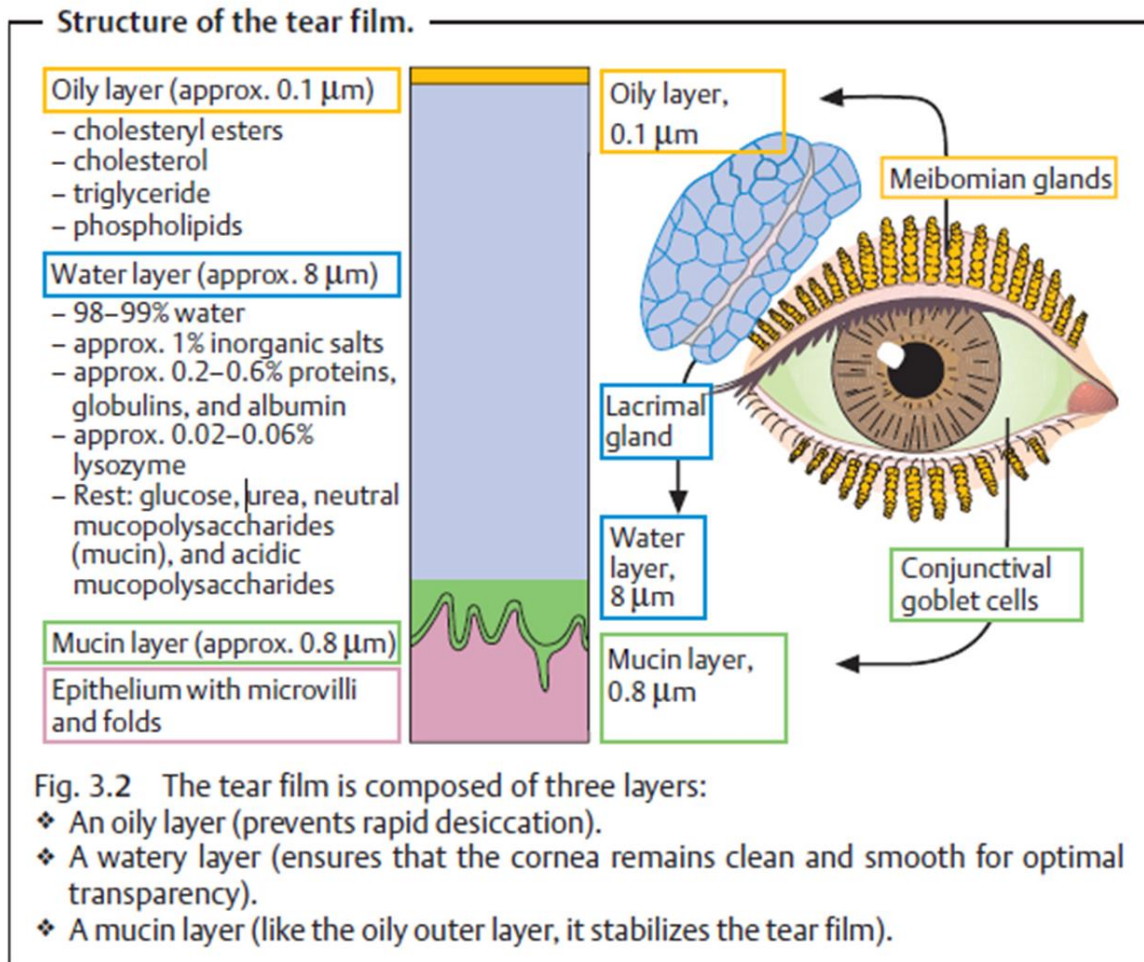
3. The **inner mucin layer** (approximately 0.8  $\mu\text{m}$  thick) is secreted by the *goblet cells of the conjunctiva* and the *lacrimal gland*.

- It is hydrophilic with respect to the microvilli of the corneal epithelium, which also helps to *stabilize the tear film*.

**This layer**

- A. Prevents the watery layer from forming beads on the cornea
- B. Ensures that the *watery layer moistens the entire surface of the cornea and conjunctiva*.

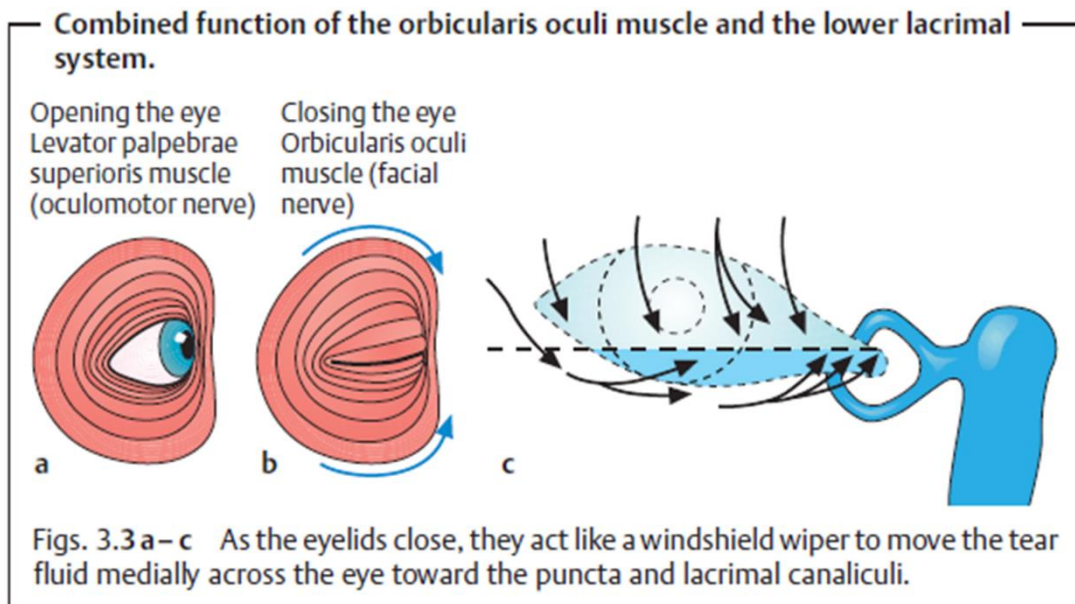
Lysozyme, beta-lysin, lactoferrin, and gamma globulin (IgA) are **tear-specific proteins** that give the tear fluid *antimicrobial characteristics*.



### Tear drainage

The shingle-like arrangement of the **fibers of the orbicularis oculi muscle** (supplied by the facial nerve) causes the eye to close progressively from lateral to medial; instead the eyelids simultaneously closing along their entire length. This *windshield wiper motion* moves the tear fluid medially across the eye toward the medial canthus (Figs. 3.3a–c).

The **superior and inferior puncta lacrimales** collect the tears, which then drain through the superior and inferior **lacrimal canaliculi** into the **lacrimal sac**. From there they pass through the **nasolacrimal duct** into the **inferior concha** (see Fig. 3.1).



## Examination Methods

### Evaluation of Tear Formation include:

1. Schirmer tear testing
2. Tear break-up time (TBUT)
3. Rose bengal test
4. Impression cytology

### Evaluation of Tear Drainage include

1. Conjunctival fluorescein dye test
2. Probing and irrigation
3. Radiographic contrast studies
4. Digital subtraction dacryocystography
5. Lacrimal endoscopy

## Schirmer tear testing:

This test (Fig. 3.4) provides information on the **quantity of watery component in tear secretion.**

- **Test:** A strip of litmus paper is inserted into the conjunctival sac of the temporal third of the lower eyelid.
- **Normal:** After about five minutes, at least 15mm of the paper should turn blue due to the alkaline tear fluid.
- **Abnormal:** Values less than 5mm are abnormal (although they will not necessarily be associated with clinical symptoms).

## Measuring tear secretion with Schirmer tear testing.

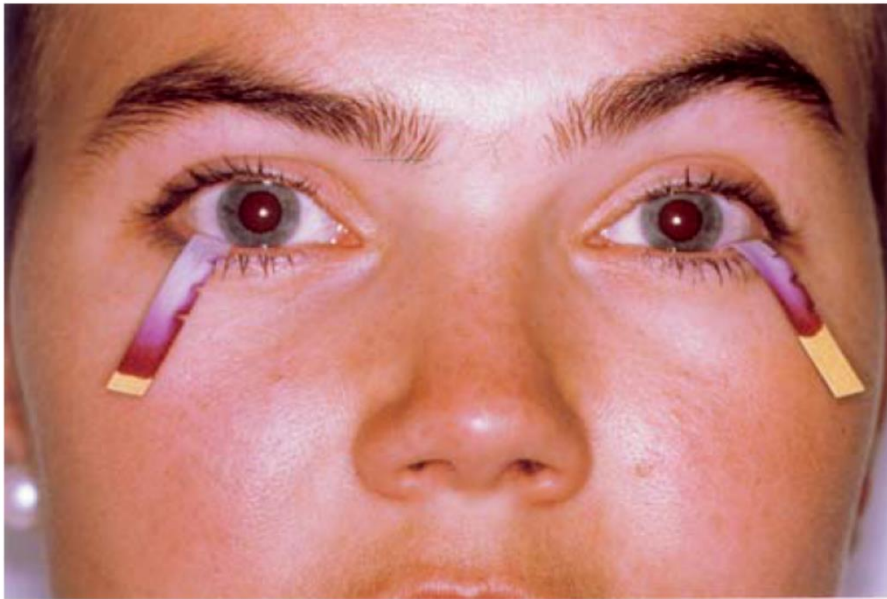


Fig. 3.4 A strip of litmus paper is folded over and inserted into the conjunctival sac of the temporal third of the lower eyelid. Normally, at least 15 mm of the paper should turn blue within five minutes.

### 1. Evaluation of Tear Formation include:

#### Tear break-up time (TBUT):

This test evaluates the **stability of the tear film**.

- **Test:** Fluorescein dye (10  $\mu$ l of a 0.125% fluorescein solution) is added to the precorneal tear film. The examiner observes the eye under 10–20 power magnification with slit lamp and cobalt blue filter and notes when the first signs of drying occur **(i) without the patient closing the eye** and **(ii) with the patient keeping the eye open as he or she would normally**.
- **Normal:** TBUT of *at least* 10 seconds is normal.

#### Rose bengal test:

- Rose bengal **dyes dead epithelial cells and mucin**. This test has proven particularly useful in evaluating *dry eyes* (keratoconjunctivitis sicca) as it reveals conjunctival and corneal symptoms of desiccation.

#### Impression cytology:

- A Millipore filter is fastened to a tonometer and pressed against the superior conjunctiva with 20–30mm Hg of pressure for two seconds. The **density of goblet cells** is estimated under a microscope (*normal density* is 20–45 goblet cells per square millimeter of epithelial surface).
- The number of mucus-producing goblet cells is reduced in various disorders such as keratoconjunctivitis sicca, ocular pemphigoid, and xerophthalmia.

## 2. Evaluation of Tear Drainage include

### Conjunctival fluorescein dye test:

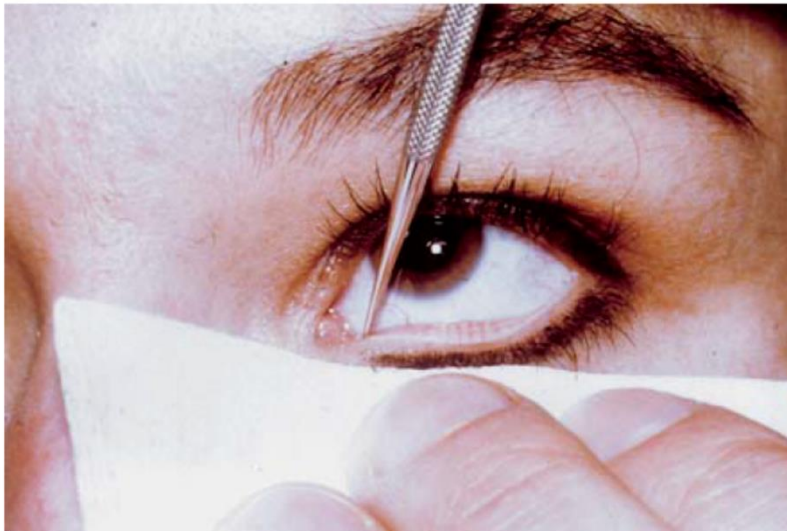
- Normal **tear drainage** can be demonstrated by having the patient blow his or her nose into a facial tissue following application of a 2% fluorescein sodium solution to the inferior fornix.

### Probing and irrigation:

These examination methods are used to **locate stenoses**.

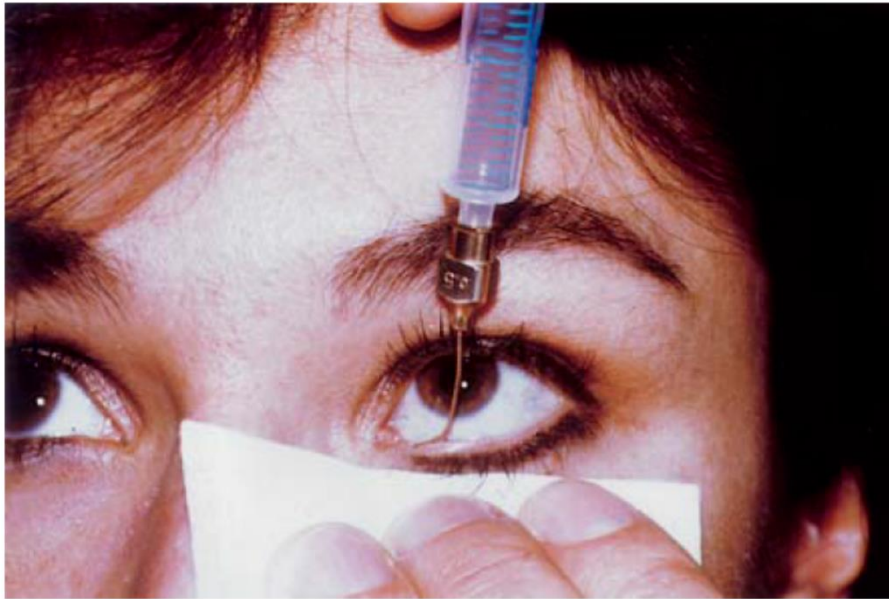- After application of a topical anesthetic, a conical probe is used to dilate the punctum. Then the lower lacrimal system is flushed with a physiologic saline solution introduced through a blunt cannula (Figs. 3.5 a and b).
- If the passage is *unobstructed*, the solution will drain freely into the nose.
- Canalicular stenosis will result in reflux through the irrigated punctum.
- If the stenosis is deeper, reflux will occur through the opposite punctum (Fig. 3.6).
- A probe can be used to determine the site of the stricture, and possibly to eliminate obstructions (Fig. 3.7).

Irrigation of the lower lacrimal system under topical anesthesia.

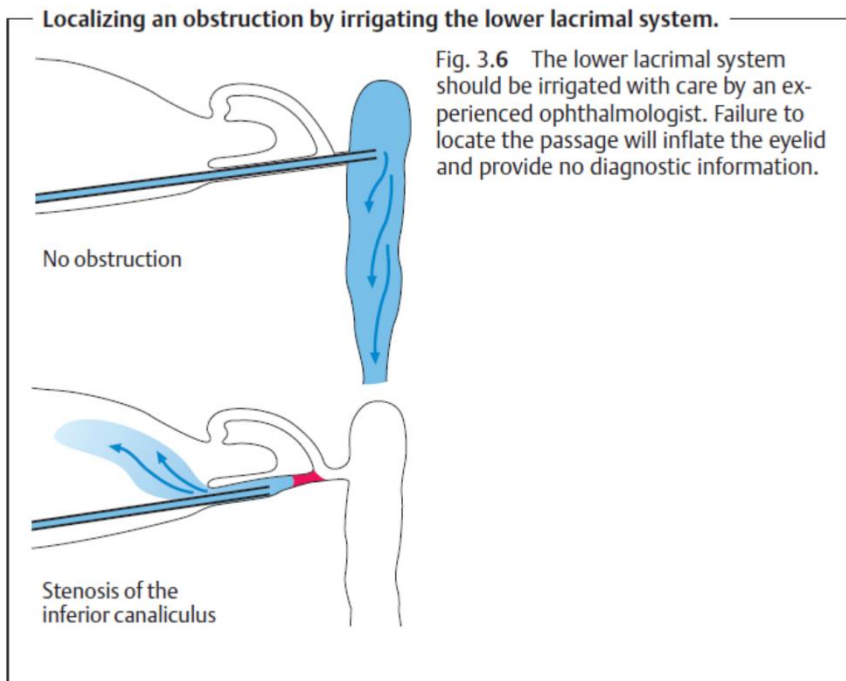


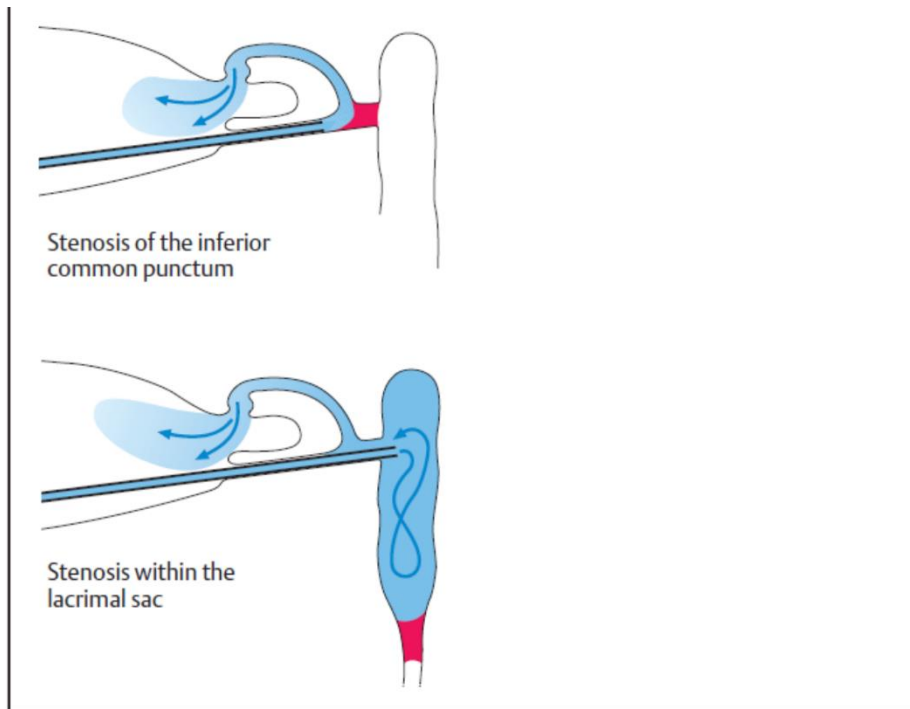
a

Figs. 3.5 a and b First the punctum is dilated by rotating a conical probe. Then the lacrimal passage is flushed with a physiologic saline solution. The examiner should be particularly alert to good drainage or possible reflux.

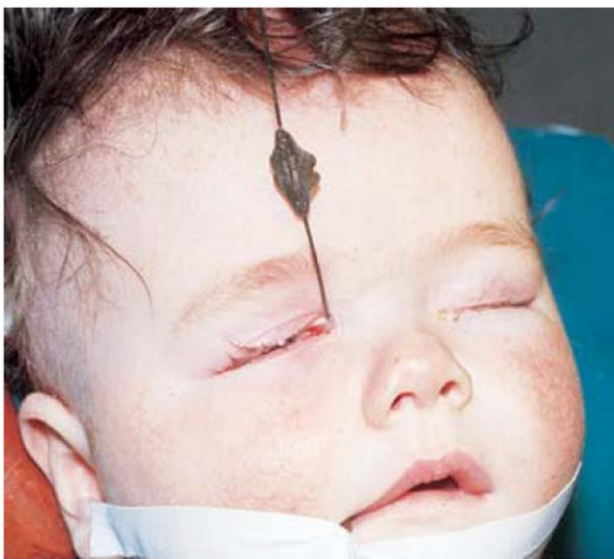

b

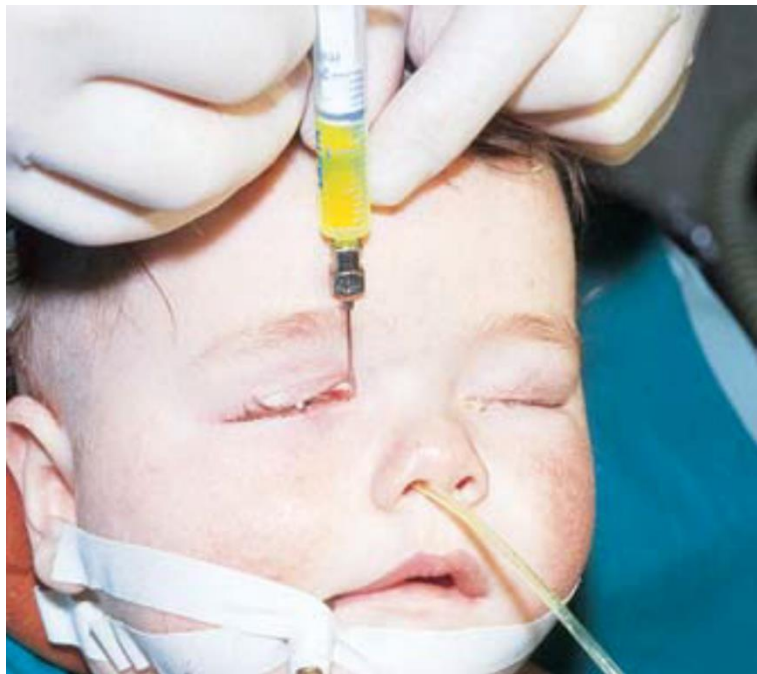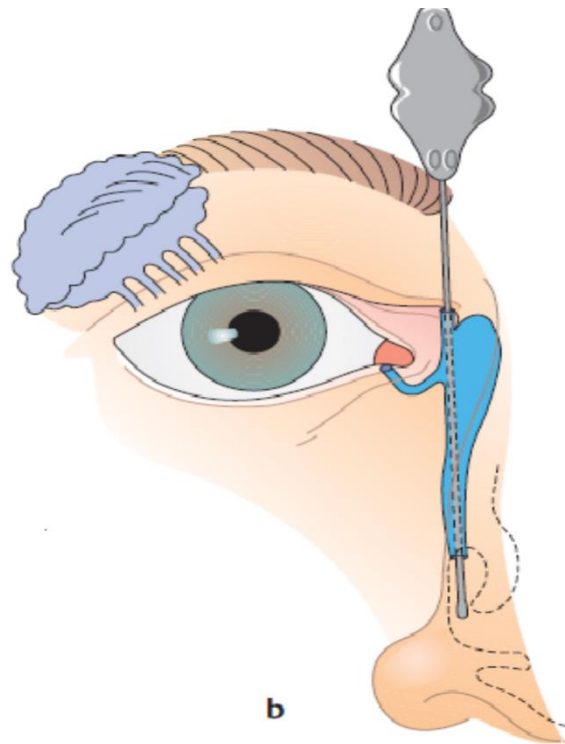




Opening a stenosis of the lower lacrimal system with a probe.







Figs. 3.7a–c After application of a topical anesthetic, the probe is carefully introduced into the lower lacrimal system. The puncta are dilated and then the valve of Hasner is opened (a and b). A dye solution can then be introduced to verify patency of the lower lacrimal system (c). In infants six months or older, the procedure is best performed under short-acting general anesthesia.

### Radiographic contrast studies:

Radiographic contrast medium is instilled in the same manner as the saline solution. These studies demonstrate the **shape, position, and size** of the passage and possible **obstructions to drainage**.

### Digital subtraction dacryocystography:

These studies demonstrate only the contrast medium and image the lower lacrimal system without superimposed bony structures. They are particularly useful as **preoperative diagnostic studies** (Fig. 3.8).

Radiographic image of the lower lacrimal system.

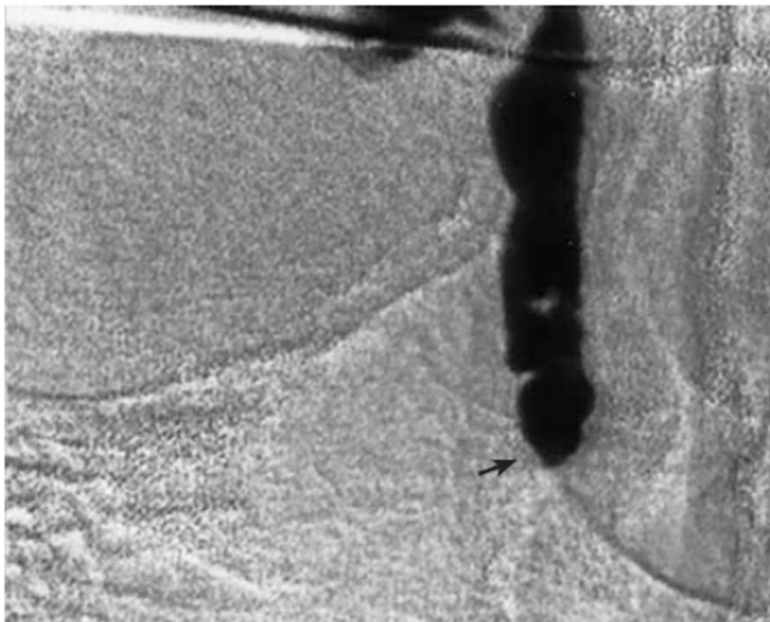


Fig. 3.8 Digital subtraction dacryocystography images the lower lacrimal system and can demonstrate a possible stenosis (arrow) without superimposed bony structures.

### Lacrimal endoscopy:

Fine endoscopes now permit **direct visualization of the mucous membrane of the lower lacrimal system**. Until recently, endoscopic examination of the lower lacrimal system was not a routine procedure.

Muqdad fuad